国家儿童医学中心
National Center for Children's Health, China

北京儿童医院
BEIJING CHILDREN'S HOSPITAL

北京儿童医院顺义妇儿医院
Shunyi Women's and Children's Hospital of Beijing Children's Hospital

A case report of bone marrow transplantation treatment for a RDEB patient in China

Zhe Xu MD PhD

Department of Dermatology

Beijing Children's Hospital

Capital Medical University

National Center for Children's Health

Speaking topics

1. Introduction of Beijing Children's Hospital

2. bone marrow transplantation （BMT） treatment for a RDEB patient in China

History of Beijing Children's Hospital

- Established in June 1, 1942
- Private Beijing Children's Hospital, 75 years

National Center for Children's Health

- A hospital continuum
- 20 hospitals in the whole country

Epidermolysis bullosa (EB)

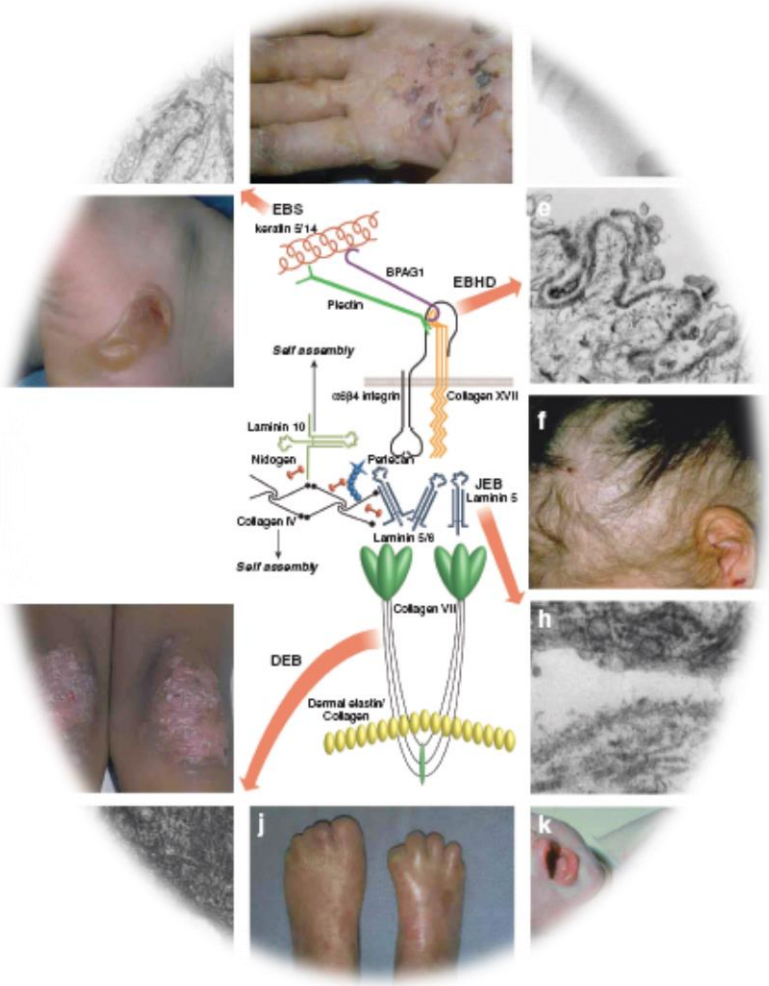

- A group of genodermatoses that can cause blister formation from mutations in the genes of anchor proteins in the basement membrane zone

- Suitable treatments for severe subtypes of EB have not been established other than symptomatic therapies

Classification of EB

Major EB type	Major EB subtype	Minor EB subtype	Targeted protein (S)
Epidermolysis bullosa simplex	Suprabasal EBS	Lethal acantholytic EB	Desmoplakin
	Basal EBS	Plakophilin deficiency	Plakophilin -1
		EB superficialis	?
		EBS-localized	K5, K14
		EBS-Dowling Meara	K5, K14
		EBS-other generalized	K5, K14
		EBS with mottled pigmentation	K5
		EBS with muscular dystrophy	Plectin
		EBS with pyloric atresia	Plectin, α6β4 integrin
		EBS, autosomal recessive	K14
		EBS ogna	Plectin
		EBS, migratory circinate	K5
Junctional epidermolysis bullosa	JEB-Herlitz	-	Laminin-332
	JEB, other	JEB-non-herlitz, generalized	Laminin-332
		JEB-Non-herlitz, localized	Type XVII collagen
		JEB-Pyloric atresia	α6β4 integrin
		JEB, inversa	Laminin-332
		JEB, late onset	?
		LOC syndrome	Laminin-332
Dystrophic epidermolysis bullosa	Dominant DEB	DDEB, generalized	Type VII collagen
		DDEB, acral	
		DDEB, pretibial	
		DDEB, pruriginosa	Type VII collagen
		DDEB, nails only	
		DDEB, bullous dermolysis of newborn	
	Recessive DEB	RDEB, severe generalized	
		RDEB, generalized other	
		RDEB, inversa	
		RDEB, pretibial	
		RDEB, pruriginosa	
		RDEB, centripetalis	
		RDEB, bullous dermolysis of newborn	
Kindler syndrome	-		

EB: Epidermolysis bullosa, EBS: Epidermolysis bullosa simplex, JEB: Junctional epidermolysis bullosa, DEB: Dystrophic epidermolysis bullosa, DDEB: Dominant dystrophic epidermolysis bullosa, RDEB: Recessive dystrophic epidermolysis bullosa

Sarkar R et al. Indian J Dermatol Venereol Leprol 2011;77:431-438

Strategies for the treatment of severe EB

GENE

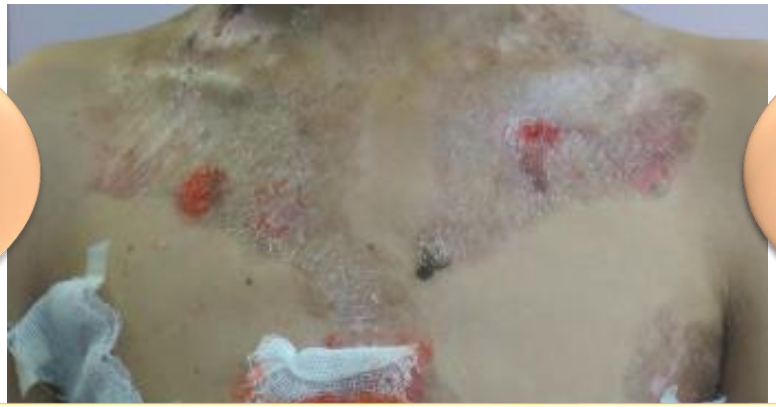

PROTEIN

mutations in the genes of anchor proteins in the basement membrane zone

CELL

DRUG

Stem Cells Changing Their Plans

1. First stem cell therapy:

→ Leukemia

2. First gene cell therapy:

→ Lysosomal diseases

3. Using blood to regenerate skin:

→ Epidermolysis bullosa

Medawar's Rules



Peter Medawar
[1915-1987]

- ✓ Start with a practical problem that can be solved
- ✓ See inexplicable data as potential discovery in disguise
- ✓ Draft and explanation and show the proof
- ✓ Expand the theory
- ✓ Make it clinically meaningful

What help the REDB in BMT?

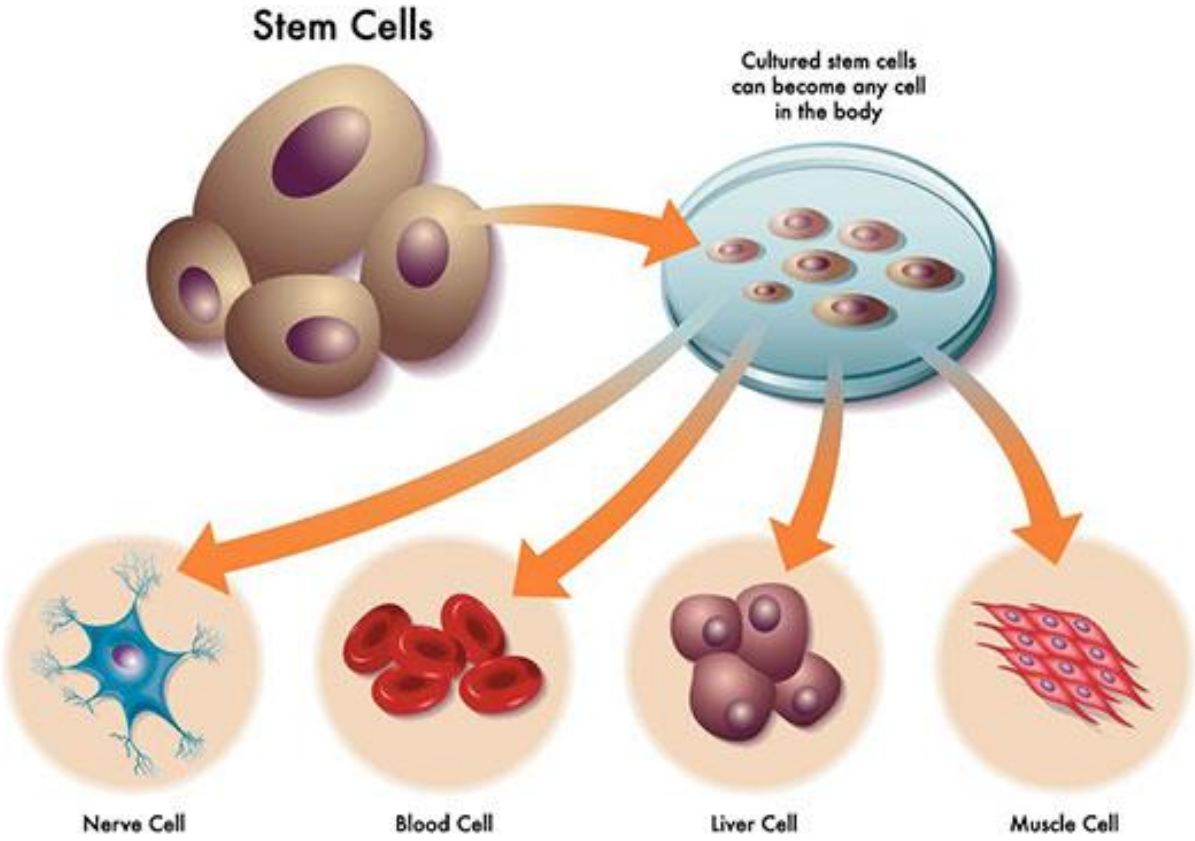

- **Bone marrow stem cells -- Allograft has normal BMZ genes.**
- **Cell-derived keratinocytes.**
- **Producing normal BMZ proteins? Amelioration of EB?**

Animal experiments: BMT into EB model mice!

- BM CD150+, CD48- cells homed to skin to produce C7 and anchoring fibrils

- Embrionic BMT (E-BMT) to C7 knockout mice

- Accelerated wound healing and new C7 at dermal–epidermal junction at 4months

Tolar J, et al. Blood 2008; 113(5), 1167–1174.
Chino T et al., Am J Pathol 2008; 173:803–814
Conget P, Cytotherapy 2010; 12(3), 429–431.

RDEB cell therapy for patients: evidence for new C7

Replenishment of type VII collagen and re-epithelialization of chronically ulcerated skin after intradermal administration of allogeneic mesenchymal stromal cells in two patients with recessive dystrophic epidermolysis bullosa.

Cytotherapy 2010 May;12(3):429-431.

Bone marrow transplantation for recessive dystrophic epidermolysis bullosa.

N Engl J Med. 2010 Aug 12;363(7):629-639.

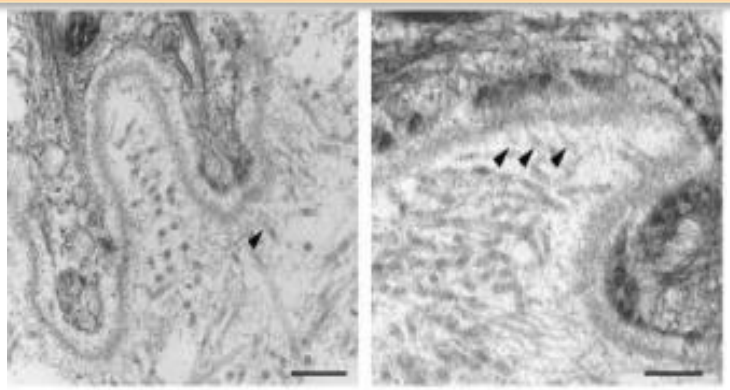

Bone marrow treatment for a RDEB patient in China

- **A 12-year-old girl**
- **Complaints: From birth on, she has painful erosions and blisters on mucosal membranes and skin, often resulting mutilating scars, local and systemic infections, fusion of fingers and toes**
- **Medical history:**
  - **Clinical diagnosis of RDEB when she was 4 yrs**
  - **The care of this patient has been palliative and restricted to the treatment of individual wounds**

• 2 yrs

She said: I'm afraid going to die.

• 12 yrs

Before BMT

Methods

- Light microscopy of skin biopsy. It shows subepidermal blister

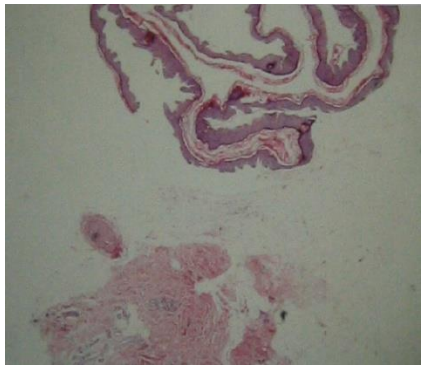

- Immunofluorescence staining of the skin, type Ⅶ collagen is completely lost

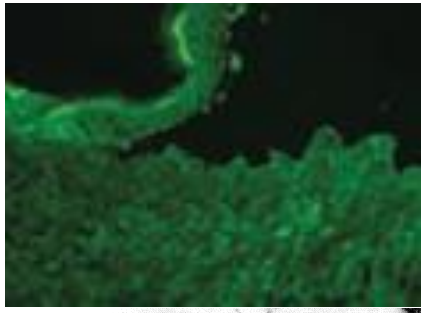

- Subepidermal, dermolytic split formation of initial blister (x15,000).
- Two nonsense mutations of *COL7A1*, R2510X and R525X in typeⅦ collagen

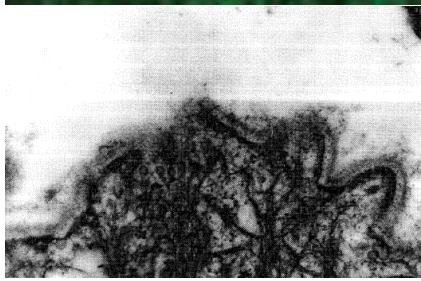

- Diagnosis : recessive dystrophic epidermolysis bullosa

Prepare before BMT

- Nursing care of skin and mucous membrane of the affected area of the patient
- Nutrition support
- Skin and mucous membrane anti-infection treatment
- Treatment of residual root of tooth extraction
- Total body irradiation pretreatment

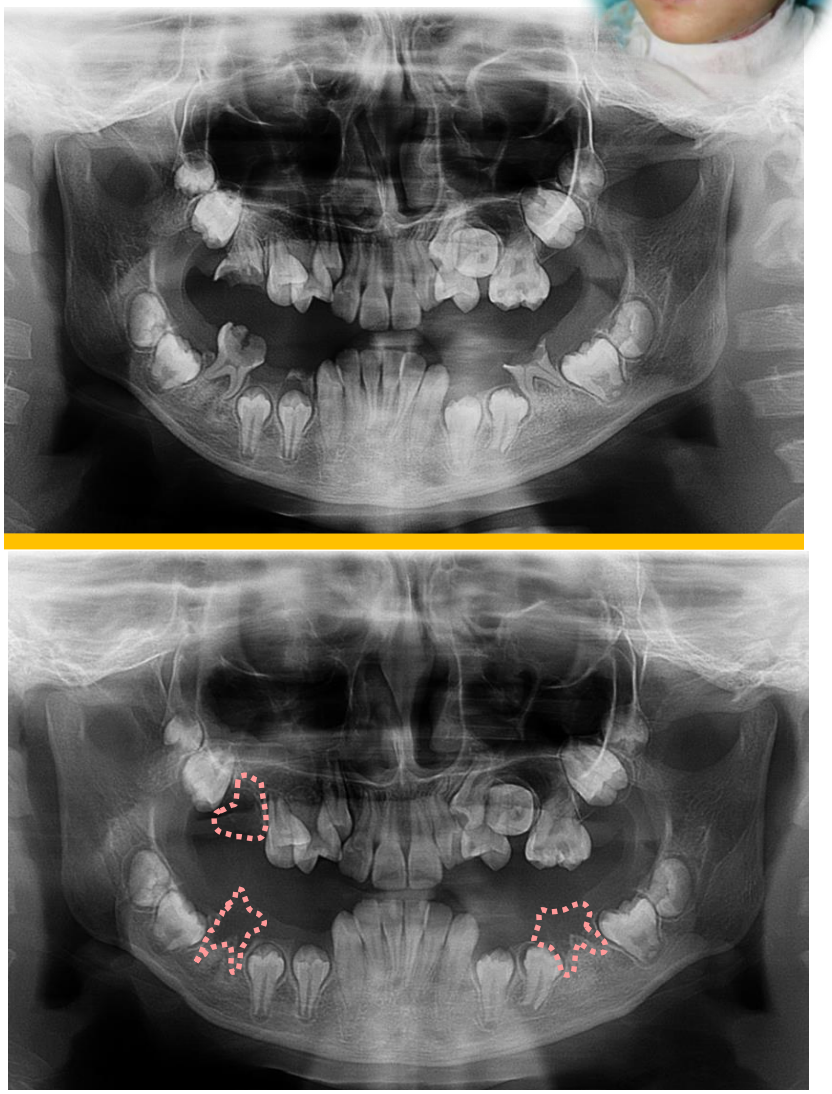

Transplantation Regimens of BMT

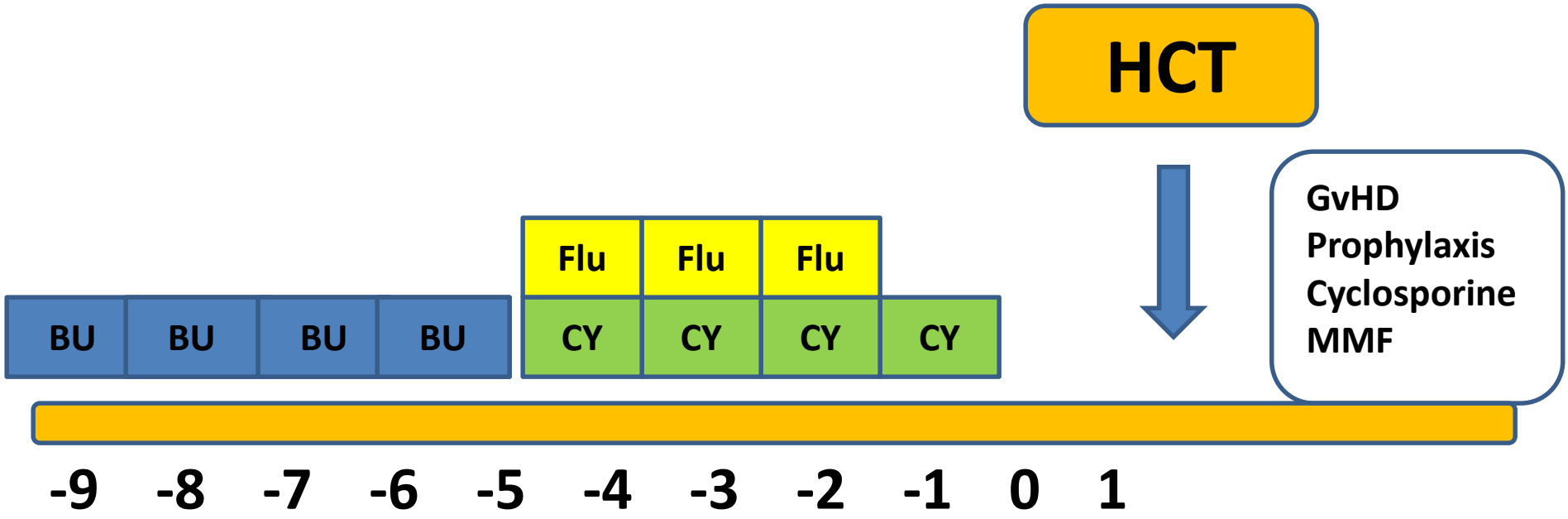

- **Donor selection: HLA10/10 match independent donor**
- **Short course of prepare and treatment**

Results

- White blood cell implantation time: 13 days
- Platelet engraftment time: 20 days
- Evidence of implantation :

  +30 days , complete donor type HLA

- Blisters and erosions were better than before, reduce skin aging, esophagus and eye mucosal fragility significantly improved
- Symptomatic treatment of graft versus host reaction: Hemolytic anemia

Results



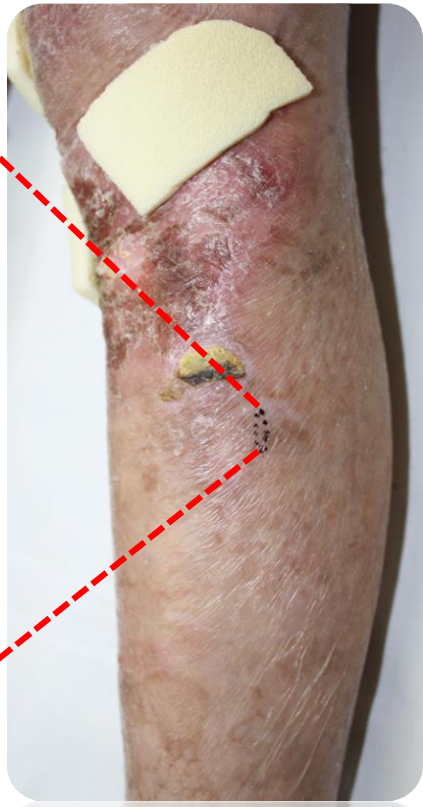

C7 is expressed in skin after 12 months of treatment

- Merged images with blue DAPI nuclear stain (col7 indicated with the vertical arrow)
- Merged images demonstrate the GFP collagen type VII after 12 months BM infusion

Skin contrast before and after transplantation

- Before
  + 6 months
  + 3 months

Skin contrast before and after transplantation

- Before
  + 6 months
  + 3 months

- + 3 months

+ 6 months

• + 3 months

+ 6 months

- + 12

When I want to eat bread, I can eat it.

Future – call for public participation

The third National Conference of EB patients.

Future - call for Teamwork



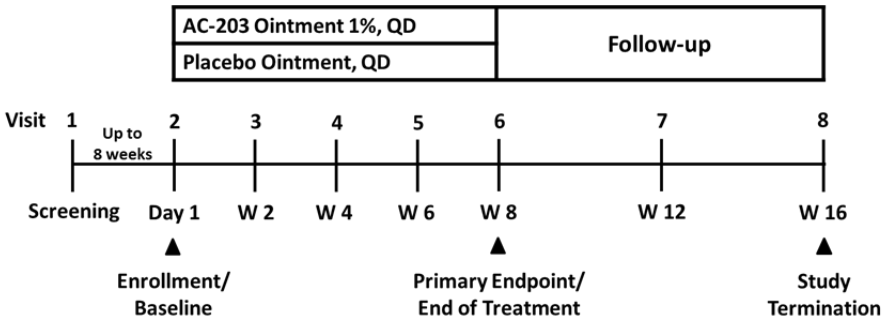

DebRA CHINA -- founded in 2013

Participate in new drug test

http://www.debra.org.cn/

国家儿童医学中心
National Center for Children's Health, China

北京儿童医院
BEIJING CHILDREN'S HOSPITAL

北京儿童医院顺义妇儿医院
Shunyi Women's and Children's Hospital of Beijing Children's Hospital

Thank You for Attention